

Case Report / *Olgu Sunumu*

Complete uterine prolapse in a cat

Firdevs BİNLİ^{1,a}, Fatih BÜYÜKBUDAK^{1,b}, İpek İNAN^{1,c}, Murat FINDIK^{1,d}, Serhan Serhat AY^{1,e}

¹University of Ondokuz Mayıs, Faculty of Veterinary, Department of Obstetrics and Gynecology, Samsun, Turkey.

^aORCID: 0000-0001-9547-8776; ^bORCID: 0000-0002-6993-2514; ^cORCID: 0000-0002-9215-5055;

^dORCID: 0000-0003-1408-2548; ^eORCID: 0000-0003-2116-5149.

✉Corresponding Author: firdevsbinli@gmail.com

Received date: 28.01.2021 - Accepted date: 21.08.2021

Abstract: In this case, it was presented a case of complete uterine prolapse in a cat following a third parturition at the age of 18 months. Upon physical examination complete uterine prolapse was diagnosed due to a mass protruding from the vulva which included both uterine horns. After the invagination and eversion were corrected and the uterus was relocated to its anatomical position, ovariohysterectomy was performed. Sutures were removed ten days after the operation. Following shrinking of uterus by using the hypertonic fluid and repositioning, ovariohysterectomy is a suitable and reliable option for cats with complete uterine prolapse.

Keywords: Cat, ovariohysterectomy, parturition, uterine prolapse.

Bir kedide tam uterus prolapsusu

Özet: Bu olguda, üçüncü doğumunu takiben tam uterus prolapsusu şekillenen 18 aylık bir kedi sunulmaktadır. Fiziksel muayenede, her iki kornu uteriği içeren bir kitlenin vulvadan dışarı çıkması sebebiyle tam uterus prolapsusu tanısı konuldu. İnvaginasyon ve eversiyon düzeltilip uterus anatomik pozisyonuna getirildikten sonra ovariohisterektomi yapıldı. Operasyondan 10 gün sonra dikişler alındı. Hipertonik sıvı kullanılarak uterus küçültüldükten ve yeniden pozisyon verildikten sonra, ovariohisterektomi tam uterus prolapsusu olan kediler için uygun ve güvenilir bir seçenektir.

Anahtar sözcükler: Doğum, kedi, ovariohisterektomi, uterus prolapsusu.

Uterine prolapse, rarely observed and infrequently reported in queens (10, 12), usually occurs before and during, or immediately after parturition/abortion or within 48 hours following parturition/abortion as an emergency situation in primiparous (10) and multiparous cats (1, 9). The complication can be seen in two forms: a complete or bilateral form in which both uterine horns prolapse, or a unilateral form in which one uterine horn with or without the uterine body prolapses (10, 12). Although definitive cause of uterine prolapse is unknown, the possible factors include excessive relaxation and stretching of the pelvic muscles, excessive dilatation of the cervix, uterine atony due to metritis, incomplete separation of placental membranes, severe tenesmus, mesovarium weakness, and rupture of the mesometrium (1, 10, 11). Treatment options are determined according to the degree of tissue necrosis or ischemia, that is, the severity of tissue damage. In the treatment, amputation of the prolapsed uterus, manual reduction and repositioning, oxytocin injection, local

hyperosmotic fluid massage (50% dextrose), manual reduction with laparotomy and ovariohysterectomy (OHE) are used alone or in combination (1, 4, 10, 11). In this case report, the treatment protocol for complete uterine prolapse in a cat after parturition is described.

This case involved an 18-month-old calico cat presented to our clinic with complaints of a persistent vaginal mass, weakness, loss of appetite, and poor general condition. Information obtained from the anamnesis indicated that the cat gave birth to three live kittens three days earlier. The owner assumed that the mass emerging from the vulva was indicative of continuing parturition was and the cat was left alone. The cat had given birth to healthy kittens twice previously without experiencing dystocia.

A direct diagnosis was made after observing the protrusion of the bicornuate uterus from the vulva. The uterus was damaged, lacerated, and desiccated (Figure 1). Upon physical examination, it was determined that the cat

weighed 3.1 kg, with a body temperature of 39.3°C, heart rate 144 bpm, respiratory rate 24/min, dehydration rate 7%, and capillary refill time of three sec. The cat had leukocytosis and anemia, however, serum biochemical

parameters were within reference values (Table 1). Abdominal ultrasonography revealed that the kidneys were pulled caudally and moved away from their normal anatomical position, and the bladder was in place.

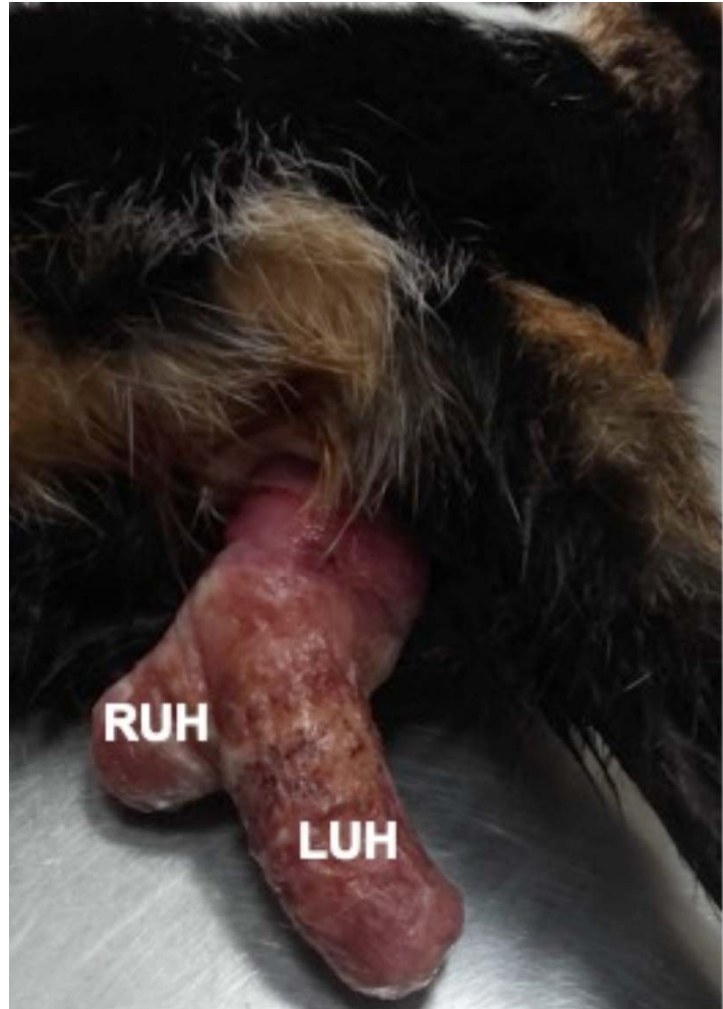

Figure 1. The appearance of the prolapsed uterus. The right uterine horn (RUH) and the left uterine horn (LUH).

Table 1. Hematological and serum biochemical values.

Hematological			Serum Biochemical		
Parameters	Value	Reference Range	Parameters	Value	Reference Range
WBC ($\times 10^9/L$)	20.63	6-17	ALP (U/L)	15	1-100
RBC ($\times 10^{12}/L$)	2.94	5.5-8.5	ALT (U/L)	37	16-60
HGB (g/dL)	4.4	11.0-19.0	CREA (mg/dL)	0.77	0.9-2.2
HCT	0.118	0.3-0.45	BUN (mg/dL)	12.5	19-34
PLT ($\times 10^9/L$)	168	117-460			
MCV (fL)	40	39-55			
MCH (pg)	14.8	13-17			
MCHC (g/L)	370	300-360			

White blood cell (WBC), red blood cell (RBC), hemoglobin (HGB), hematocrit (HCT), platelet (PLT), mean corpuscular volume (MCV), mean cell hemoglobin (MCH), mean corpuscular hemoglobin concentration (MCHC), alkaline phosphatase (ALP), alanine transaminase (ALT), creatinine (CREA), blood ure nitrogen (BUN).

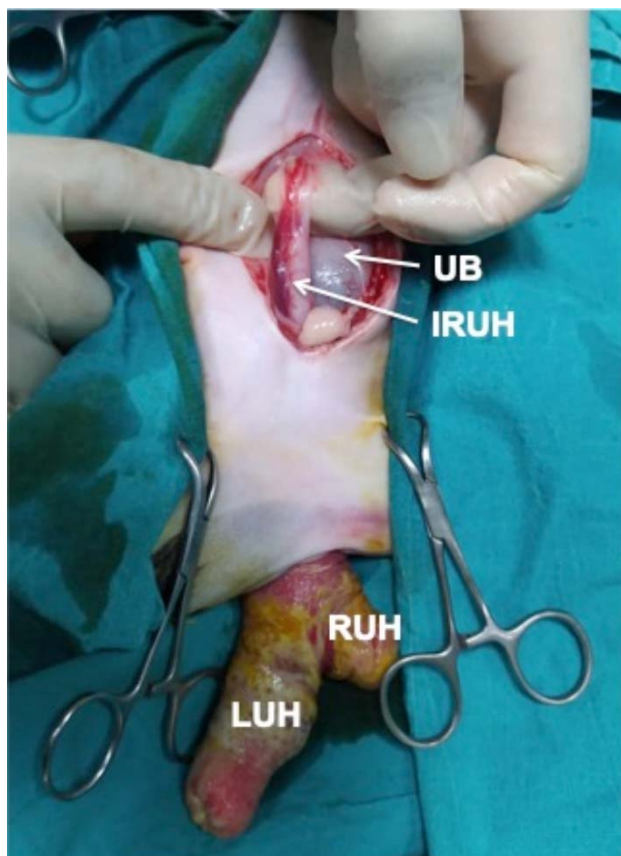


Figure 2. Invaginated right uterine horn (IRUH) was observed above the urine bladder (UB), right uterine horn (RUH), left uterine horn (LUH).

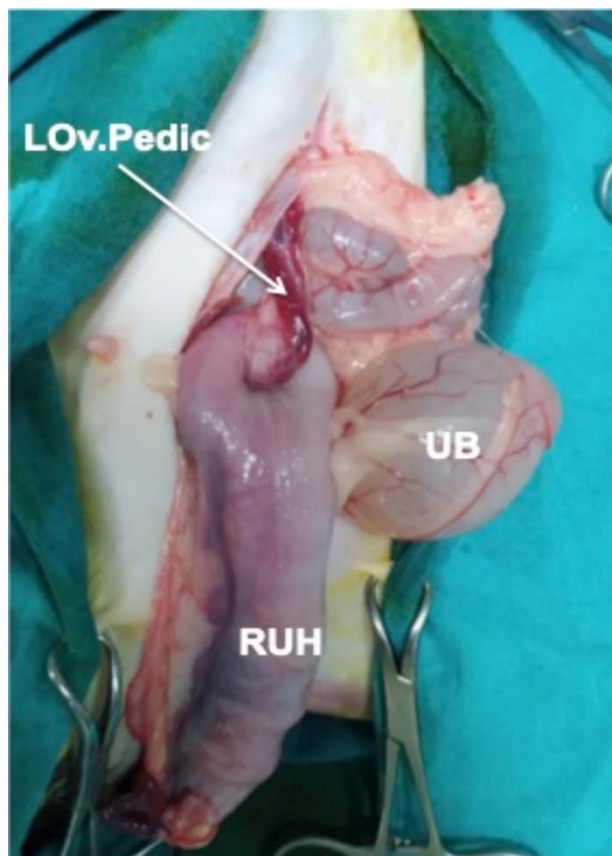


Figure 3. The view after correcting the invaginated right uterine horn. As a result of eversion of the left uterine horn, only the ovary and its pedicle (LOv.Pedic) were visible, right uterine horn (RUH), urinary bladder (UB).

It was decided to perform OHE after the prolapsed uterus was repositioned to its anatomical position in the abdomen by laparotomy. The cat was treated preoperatively with intravenous Lactated Ringer's solution (Polifleks®; Polifarma, Turkey and supportive maintenance therapy solutions (Duphalyte®; Zoetis, Spain 10 ml/kg/hour), and amoxicillin and clavulanic acid combinations (Amoklavin®; Deva, Turkey) at the dose of 20 mg/kg twice daily perorally. The prolapsed uterus was washed with saline solution and kept under a compress of hyperosmotic fluid (20% dextrose solution; Dekstroz; Polifarma, Turkey) for 25-30 min to facilitate repositioning by reducing uterine edema. Anesthesia was induced with propofol (Fresenius®; Kabi, Turkey 1%, 6 mg/kg/iv) and maintained with isoflurane (Forane®; Piramal, USA) and 100% O₂ after intubation. Intraoperative analgesia was managed with a constant-rate infusion (CRI) of a combination of saline, ketamine (Ketasol®; İnterhas, Turkey and butorphanol (Butomidor®; İnterhas, Turkey) (500 ml + 35 mg + 12 mg, respectively) at a rate of 10 ml/kg/hour. The surgery was performed by midline incision as a non-complicated OHE. During the procedure, it was determined that the right

ovary was displaced to the caudo-dorsal side of the abdomen and the pedicle was stretched. On the other hand, the left ovary, accompanied by a severely stretched pedicle was found in a deep caudal position but with no pedicle rupture (Figure 2). The right horn was partially invaginated and the left horn was everted with the corpus uteri (Figure 3). First, the right cornu uteri was carefully retracted and the right side invagination was corrected. Then the left uterine horn was grasped and its eversion was corrected and both horns were brought to their normal anatomical position. During the correction of the invagination and the eversion processes, no resistance to pulling the uterine tissue or caudal reproductive tract (vulva or vagina) was encountered. Finally, a routine OHE was performed. In the postoperative period, fluid therapy and antibacterial treatment were continued for a week. Urination started within the first postoperative hour and the cat began to eat and drink the following day. The skin sutures were removed ten days later and hospitalization ended.

As a periparturient complication, prolapse uteri is rarely encountered in cats (12). According to Extrand and Linde-Forsberg (3), uterine prolapse cases are responsible

for 0.6% of maternal dystocia (3). At the same time, it is thought that predisposition factors such as dystocia, severe uterine and abdominal contractions, insufficient placental separation, a continuation of postpartum tenesmus, and loosening or rupture of uterine ligaments due to recurrent pregnancies play a crucial role in such cases (1, 4, 5, 12). Besides, body condition score (BCS) may also be an important factor. For example, uterine prolapse incidence is higher in overweight women (8) and poor BCS has an important effect on uterine or vaginal prolapse in cows (6). In this case, the patient's history was not remarkable but examination and operative findings were sufficient for diagnosis. Therefore, although it is hard to determine the exact cause of the prolapse, we can provide information about the patient's condition. Because of the absence of dystocia findings in the history and the absence of placenta or fetal structures in uterus we focused on two points as reasons for the cat's current situation: the relationship between the cat's age and the number of parturitions, and the BCS of the cat. In the present case, the cat's third parturition at 18 months of age suggests that the cat probably conceived during the first estrus cycle and the parturition-conception intervals were very short. Besides, considering the 3.1 kg body weight, the cat had a relatively weak BCS (13). Therefore, we suggest that conceiving at an early age, repeated pregnancies and parturitions, accompanied by a weak BCS triggered the prolapse by weakening the uterine suspensory ligaments and pelvic ligaments.

Uterine prolapse requires urgent intervention because of the possibility of life-threatening situations such as hypovolemic or septic shock due to rupture of the uterine vein or uterine mucosa or to maintain fertility by preventing further damage to the uterus (10). In this case, prolapse had occurred immediately after complete parturition, according to anamnesis. Considering the three days between the time of development of the case and the time of admission to our clinic, the prolapsed uterus and the patient's general condition were better than expected. However, the mucosa of the prolapsed uterus was observed to be dried, wrinkled, and lacerated, and the general condition of the cat had started to deteriorate. When evaluating the hemogram, we thought the cause of mild leukocytosis could result from bacterial contamination. Still, the cause of anemia was the pregnancy and early postpartum period rather than infection. Thus, the anemia was considered normal. According to Kimura and Kotani (7), RBC and HCT values tend to decline at a moderate level after mid-pregnancy in dogs (7). Also, in this case hemogram results, were similar to those reported by Uçmak et al. (5). Treatment options of should be selected according to the

degree of uterine damage (10). Based on the literature, OHE is primary surgery in many cases (2, 5, 10, 11). In uterine prolapse in cats, there are two main OHE procedures. The surgery would be completed in one step by routine OHE after repositioning the prolapse by laparotomy (10), or amputation of the prolapsed uteri would be done after ovariectomy (2). In this case, we preferred the first option. After the correction of invagination and eversion, and the uterus was brought to its anatomical position, an OHE was performed. The hypertonic solution, which was administered to the prolapsed tissue, reduced the mass volume and made insertion easier. Although no information was provided about the operation time and the advantages of the method in previous publications, the procedure we followed, in this case, required less labor than the two-stage process (2). Also, we think a shorter duration of anesthesia has advantages, such as reducing the risks of complications such as hypovolemia, hypothermia, infection, or death. As a treatment option, the repositioning procedure and bringing the uterus to the anatomical position without OHE could be attempted; however, we preferred the OHE due to lacerations in the uterine mucosa, the risk of infection, and the possibility of recurrence in later deliveries in addition to the request of the owner.

This case showed that uterine prolapse could continue to exist for up to three days without life-threatening consequences. Undoubtedly, this case is an individual situation, and uterine prolapse typically requires urgent intervention because it is life-threatening. In such cases, OHE is a suitable and reliable option that can be performed after quickly repositioning the uterus made possible by keeping it in hypertonic fluid before surgery.

Financial Support

The authors received no financial support for the research, authorship, and/or publication of this article.

Ethical Statement

This work involved the use of non-experimental animal only (including owned). Established internationally recognized high standards ('best practice') of individual veterinary clinical patient care were followed. Ethical approval from a committee was therefore not necessarily required.

Conflict of Interest

The authors declared no potential conflicts of interest concerning the research, authorship, and/or publication of this article.

References

1. **Bigliardi E, Di Ianni F, Parmigiani E, et al** (2014): *Complete uterine prolapse without uterine mucosal eversion in a queen*. J Small Anim Pract, **55**, 235-237.
2. **Deroy C, Bismuth C, Carozzo C** (2015): *Management of a complete uterine prolapse in a cat*. J Feline Med Surg Open Reports, 1-4.
3. **Ekstrand C, Linde-Forsberg C** (1994): *Dystocia in the cat: A retrospective study of 155 cases*. J Small Anim Pract, **35**, 459-464.
4. **Feldman EC, Nelson RW** (2004): Periparturient diseases. 808. In: Feldman EC and Nelson RW (Eds), *Canine and Feline Endocrinology and Reproduction*. 3th ed., Saunders, St Louis.
5. **Günay Uçmak Z, Uçmak M, Çetin AC, et al** (2018): *Uterine prolapse in a pregnant cat*. Turk J Vet Anim Sci, **42**, 500-502.
6. **Hadush A, Abdella A, Ragassa F** (2013): *Major prepartum and postpartum reproductive problems of dairy cattle in central Ethiopia*. J Vet Med Anim Health, **5**, 118-123.
7. **Kimura T, Kotani K** (2018): *Perinatal veterinary medicine-related evaluation in hematological and serum biochemical profiles of experimental beagles throughout pregnancy and parturition*. Animal Model Exp Med, **1**, 282-294.
8. **Myers DL, Sung VW, Richter HE, et al** (2012): *Prolapse symptoms in overweight and obese women before and after weight loss*. Female Pelvic Med Reconstr Surg, **18**, 55-59.
9. **Nöthling JO, Knesl O, Irons P, et al** (2002): *Uterine prolapse with an interesting vascular anomaly in a cheetah: A case report*. Theriogenology, **58**, 1705-1712.
10. **Özyurtlu N, Kaya D** (2005): *Unilateral uterine prolapse in a cat*. Turk J Vet Anim Sci, **29**, 941-943.
11. **Sabancı A, Evkuran Dal G, Enginler SÖ, et al** (2017): *Feline unilateral uterine prolapse: A description of two cases*. J Fac Vet Med Istanbul Univ, **43**, 67-70.
12. **Sharma A, Sharma R, Kumari A, et al** (2019): *Ovariohysterectomy followed by hysteropexy of gravid uterine prolapse in a female cat - a case report*. Vet Res Int, **7**, 76-78.
13. **Verbrugge A** (2009): *Nutritional modulation of carbohydrate metabolism in domestic cats (felis catus)*. PhD Thesis, Ghent University, Belgium.